Review Article

Primary Care

Benign Paroxysmal Positional Vertigo

Joseph M. Furman, M.D., Ph.D.,
and Stephen P. Cass, M.D., M.P.H.

MANY patients consult their doctors because of dizziness or poor balance. Dizziness is nonspecific; it may result from a disorder of almost any organ system. Thus, the differential diagnosis for such patients is broad and should include medical, neurologic, and otologic causes. Vertigo, which is the illusory sensation of motion of either oneself or one's surroundings, may be a component of a patient's dizziness.

Benign paroxysmal positional vertigo is one of the most common types of vertigo.[1,2] This condition presents as dizziness or vertigo of sudden onset that is provoked by certain changes in head position. The most common provocative movements are rolling over in bed, bending over, and looking upward. Although benign paroxysmal positional vertigo has long been recognized,[3,4] only more recently has its underlying pathophysiology been clarified and substantiated.[5-7] Free-floating particulate matter within the posterior semicircular canal of the vestibular labyrinth has been observed in vivo in several patients with this disorder.[7,8] This finding led to the development of an innovative bedside treatment in which the free-floating particles are moved from the posterior semicircular canal to another location within the vestibular labyrinth.[9] Such maneuvers usually provide the patient with immediate, and often long-lasting, relief from vertigo.[9-11]

Despite the seemingly simple and straightforward pathophysiology and treatment of benign paroxysmal positional vertigo, the diagnosis and treatment of this condition can be challenging. Patients may present with some but not all of the characteristic features of typical benign paroxysmal positional vertigo, and there are several variants. There are several types of maneuver to treat the condition.

TERMINOLOGY

"Benign paroxysmal positional vertigo" is the term most commonly used to describe a disease with a characteristic clinical presentation believed to be caused by free-floating particles within the posterior semicircular canal. Vertigo is an important feature of this condition. The word "benign" is used to distinguish between the types of vertigo caused by peripheral vestibular ailments and the types of vertigo caused by intracranial neoplasms. In fact, however, benign paroxysmal positional vertigo can be a severe, disabling problem or a nagging nuisance responsible for constant frustration. The term "paroxysmal" reflects an important and essential characteristic of the disorder: the vertigo is episodic rather than persistent. The use of the word "positional" implies a particular association between a patient's symptoms and his or her head position with respect to gravity. However, the symptoms associated with benign paroxysmal positional vertigo are elicited by a particular rotational movement of the head rather than by the final position of the head.

A characteristic feature of benign paroxysmal positional vertigo is an accompanying nystagmus. In the most common form of the condition, the positionally provoked nystagmus contains both torsional and vertical components. The nystagmus associated with benign paroxysmal positional vertigo has led some authors to use the term "benign paroxysmal positional nystagmus."[12]

PATHOGENESIS

Our understanding of the pathogenesis of benign paroxysmal positional vertigo has improved dramatically because of intraoperative observations of agglomerated, free-floating particulate matter in the endolymph of the posterior semicircular canal[7,8] (Fig. 1A). These observations substantiated what were previously only hypotheses that the movement of intralabyrinthine debris underlies most cases of the condition.[5,6] Earlier writings, notably by Schuknecht,[13] postulated that debris adhering to the cupula, rather than free-floating debris in the semicircular canal, was responsible.[14] However, the action of free-floating debris is the currently accepted pathophysiologic mechanism for typical benign paroxysmal positional vertigo. On the basis of electron-microscopical examination of particles obtained during surgery (Fig. 1B), the free-floating debris has been postulated to arise

From the Department of Otolaryngology, University of Pittsburgh School of Medicine, Pittsburgh (J.M.F.); and the Department of Otolaryngology, University of Colorado Health Science Center, Denver (S.P.C.). Address reprint requests to Dr. Furman at the Department of Otolaryngology, University of Pittsburgh School of Medicine, Pittsburgh, PA 15213, or at furman@pitt.edu.
©1999, Massachusetts Medical Society.

A

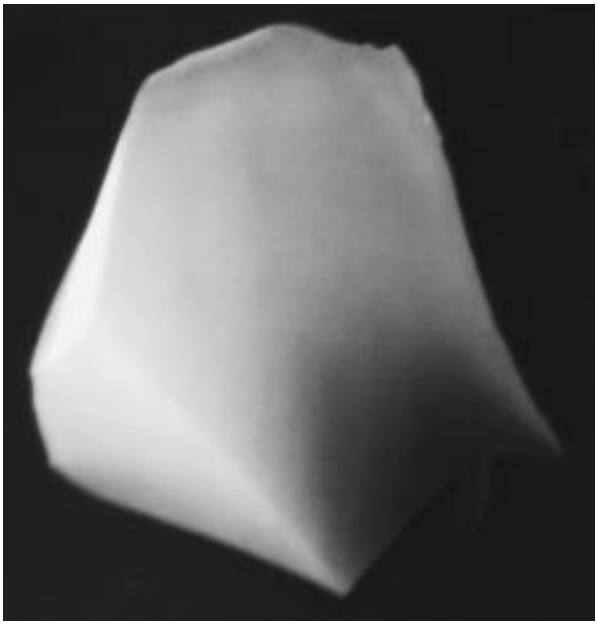

B

Figure 1. Free-Floating Particles in Patients with Benign Paroxysmal Positional Vertigo.

Panel A shows debris (arrow) in the posterior semicircular canal as observed intraoperatively (photograph courtesy of Dr. Lorne Parnes). Panel B shows a scanning electron micrograph of an intralabyrinthine particle, obtained during surgery. The debris is thought to consist of calcium carbonate crystals that originate in the utriculus of the vestibular labyrinth. Reprinted from Welling et al.,[8] with the permission of the publisher.

from within the vestibular labyrinth. The particles are most likely calcium carbonate crystals (otoliths) that are normally attached to a membrane within the utriculus, one of two gravity-sensitive structures in the inner ear.[8]

The exact mechanism by which free-floating debris leads to paroxysmal vertigo and nystagmus is unknown, but presumably the movement of the debris causes alterations in endolymphatic pressure and thus cupular deflection. Also, several studies have reported postmortem data that indicate that a small percentage of patients without an antemortem diagnosis of benign paroxysmal positional vertigo have debris in the semicircular canals.[15-17]

Despite this uncertainty, all the clinical manifestations of benign paroxysmal positional vertigo can be explained by a transitory movement of agglomerated debris within the posterior semicircular canal.[5,6,18] Moreover, this pathophysiologic process is consistent with the epidemiologic features of the condition, since head trauma is a frequent antecedent of benign paroxysmal positional vertigo,[4] presumably because of the dislocation of otoliths from the utriculus, which then migrate to the posterior semicircular canal, the most dependent structure in the vestibular labyrinth.

CLINICAL MANIFESTATIONS AND EVALUATION

Many patients report dizziness; they may also have vertigo. In some disorders, including benign paroxysmal positional vertigo, vertigo is the most prominent symptom. In other disorders, however, the vertigo is less prominent, and dizziness, lightheadedness, and dysequilibrium may better characterize the patients' symptoms. Patients with dizziness may also have impaired balance. In some neurologic disorders, poor balance may be present without dizziness. Table 1 lists the most common causes of vertigo. Benign paroxysmal positional vertigo, Meniere's disease, migraine, vertebrobasilar insufficiency, and panic disorder are associated with recurrent vertigo. They can be distinguished from one another by various characteristic symptoms. Benign paroxysmal positional vertigo is provoked by a change in position and lasts for seconds. In Meniere's disease, the vertigo occurs spontaneously, lasts for minutes to hours, and is accompanied by unilateral hearing loss and tinnitus. Migraine-associated vertigo is highly variable in duration and usually precedes or is accompanied by headache. The vertigo in vertebrobasilar insufficiency is associated

TABLE 1. COMMON CAUSES OF VERTIGO.

Otologic disorders
Benign paroxysmal positional vertigo
Meniere's disease (endolymphatic hydrops)
Vestibular neuronitis (labyrinthitis)
Neurologic disorders
Migraine-associated dizziness
Vertebrobasilar insufficiency
Panic disorder

with brain-stem symptoms such as diplopia, dysarthria, and facial numbness. Vertigo is sometimes a symptom of a panic attack. Vestibular neuronitis usually causes a single episode of vertigo that may last as long as one or two days.

The most prominent symptom of benign paroxysmal positional vertigo is vertigo that occurs in bed when a patient rolls into a lateral position.[3] Vertigo also commonly occurs when the patient is gazing upward (e.g., to place an object on a shelf) or bending forward (e.g., to tie his or her shoes). The initial onset of vertigo is often associated with nausea, with or without vomiting. Because few patients have previously had sudden, unexpected vertigo of such intensity, the symptoms may be frightening and may lead to an immediate visit to the emergency room. Typically, each episode of vertigo lasts only 10 to 20 seconds. The natural history has not been well characterized, but it appears that benign paroxysmal positional vertigo is usually a self-limited disorder that may be present for several weeks or even years, with remissions and recurrences occurring unpredictably. Most patients quickly learn to avoid the provocative head movements. This avoidance of movements that provoke vertigo is understandable but, ironically, tends to prolong the course of the condition.

Some patients with benign paroxysmal positional vertigo have a more widespread balance disorder.[4,19] A unilateral reduction in the function of the horizontal semicircular canal is found in many patients. In addition, the condition often follows head trauma or vestibular neuronitis. In these patients, labyrinthine dysfunction usually affects more than just the posterior semicircular canal, which is the portion of the inner ear affected in benign paroxysmal positional vertigo. Thus, positionally provoked vertigo may be part of a constellation of symptoms that includes gait instability and dysequilibrium during rapid head movements.

A diagnosis of benign paroxysmal positional vertigo can be established definitively through the Dix–Hallpike test[3] (sometimes erroneously called the Bárány or Nylen–Bárány test), as illustrated in Figure 2. The diagnostic criteria (Table 2) include the occurrence during the Dix–Hallpike test of a characteristic mixed torsional and vertical nystagmus with the upper pole of the eye beating toward the dependent ear and the vertical nystagmus beating toward the forehead. The nystagmus typically begins after a 1-to-2-second latency, lasts for 10 to 20 seconds, and is associated with a sensation of rotational vertigo. After the patient returns to the seated position, nystagmus is again observed, but the direction of nystagmus is reversed. Although no longer recommended as a diagnostic maneuver, because it may interfere with the immediate bedside treatment of benign paroxysmal positional vertigo, repetition of the Dix–Hallpike test results in a reduction in the intensity of vertigo and nystagmus. Observation of the patient's eye movements during the Dix–Hallpike test can be improved through the use of specialized equipment to reduce visual fixation. However, because visual suppression of torsional nystagmus is minimal,[20] the nystagmus typically associated with the disorder can, in most cases, be observed directly.

A question that often arises when assessing a patient with benign paroxysmal positional vertigo is whether there is a need for further specialized evaluation. In general, patients with this condition, especially patients who respond favorably to bedside treatment, do not require further specialized evaluation. However, patients with abnormal findings on neurologic examination, those with atypical positional nystagmus, those who do not respond to bedside treatment, and those whose dizziness or dysequilibrium cannot be attributed entirely to benign paroxysmal positional vertigo should undergo further specialized evaluation.[21,22]

EPIDEMIOLOGY

Benign paroxysmal positional vertigo has been said to be the most commonly recognized vestibular disorder[1]; in one cohort of patients, the mean age at onset was 54 years, with a range of 11 to 84 years.[4] Froehling et al. estimated that the incidence is as high as 107 cases per 100,000 population per year.[23] However, these authors did not require that patients meet strict diagnostic criteria. A study in Japan in which patients were considered to have benign paroxysmal positional vertigo only if they had nystagmus during a Dix–Hallpike test found an incidence of 10.7 cases per 100,000 per year.[24] In two other studies, the percentages of patients who presented to a specialty dizziness clinic who were found to have benign paroxysmal positional vertigo were in nearly complete agreement, with 17 percent in one study[25] and 18 percent in the other.[11] Common antecedents of the disorder include vestibular neuronitis and head trauma. In our experience, there is an association with vestibular neuronitis in 10 percent of patients and with head trauma in 20 percent of patients. Similarly, Baloh et al. reported that 15 percent of cases of benign paroxysmal positional vertigo followed neurolabyrinthitis and 18 percent followed head trauma.[4] However, in most patients with benign paroxysmal positional vertigo, no antecedent association is found.[4]

OTHER DISORDERS

Although the vast majority of patients who present with paroxysmal positionally provoked vertigo associated with transitory nystagmus have benign paroxysmal positional vertigo, a small fraction of patients have other disorders. The most common, horizontal-canal benign positional vertigo, is a disorder thought to be caused by free-floating debris in the horizontal rather than posterior semicircular canal.[26-29]

Infrequently, patients with paroxysmal positional-

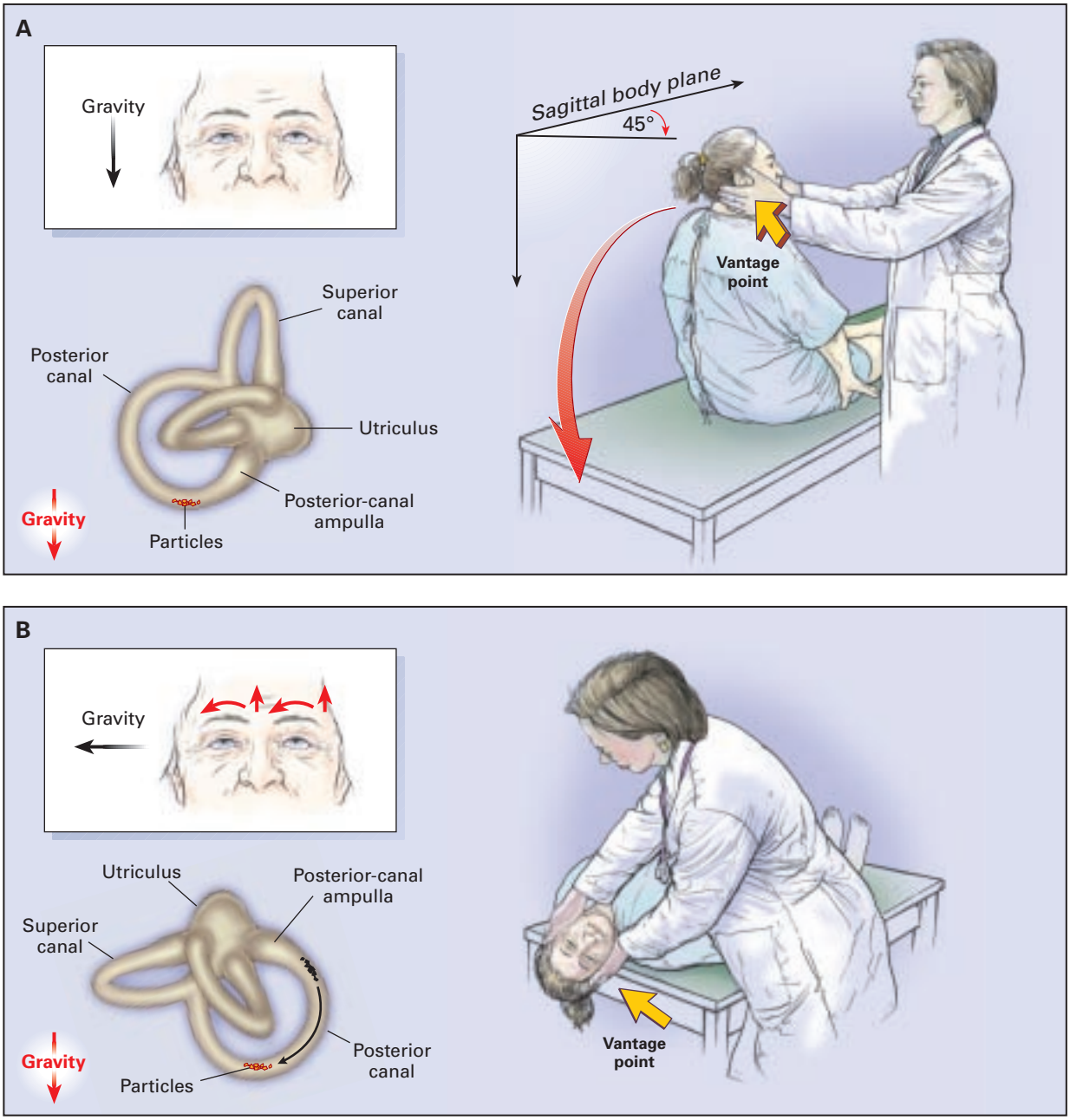

Figure 2. The Dix–Hallpike Test of a Patient with Benign Paroxysmal Positional Vertigo Affecting the Right Ear.

In Panel A, the examiner stands at the patient's right side and rotates the patient's head 45 degrees to the right to align the right posterior semicircular canal with the sagittal plane of the body. In Panel B, the examiner moves the patient, whose eyes are open, from the seated to the supine right-ear-down position and then extends the patient's neck slightly so that the chin is pointed slightly upward. The latency, duration, and direction of nystagmus, if present, and the latency and duration of vertigo, if present, should be noted. The red arrows in the inset depict the direction of nystagmus in patients with typical benign paroxysmal positional vertigo. The presumed location in the labyrinth of the free-floating debris thought to cause the disorder is also shown.

TABLE 2. DIAGNOSTIC CRITERIA FOR BENIGN PAROXYSMAL POSITIONAL VERTIGO.

Vertigo associated with a characteristic mixed torsional and vertical nystagmus provoked by the Dix–Hallpike test
A latency (typically of 1 to 2 seconds) between the completion of the Dix–Hallpike test and the onset of vertigo and nystagmus
Paroxysmal nature of the provoked vertigo and nystagmus (i.e., an increase and then a decline over a period of 10 to 20 seconds)
Fatigability (i.e., a reduction in vertigo and nystagmus if the Dix–Hallpike test is repeated)

ly provoked symptoms have an underlying disorder of the central nervous system rather than an ailment of the peripheral vestibular system.[12,21,22,30] In rare instances, patients with tumors of the posterior fossa present with vertigo and nystagmus that are indistinguishable from those found in benign paroxysmal positional vertigo.[22]

TREATMENT

The treatment currently recommended for benign paroxysmal positional vertigo is based on a bedside maneuver introduced by Epley.[9] The purpose of the maneuver, shown in Figure 3, is to relocate free-floating debris from the posterior semicircular canal into the vestibule of the vestibular labyrinth, where it presumably adheres, thus no longer causing vertigo on movement of the head. The maneuver takes advantage of the fact that the free-floating debris has a density that exceeds that of the surrounding endolymph. As a result, the debris can be moved within the labyrinth noninvasively through a sequence of head orientations with respect to gravity. Severe neck disease, a high-grade carotid stenosis, and unstable heart disease are contraindications to the maneuver shown in Figure 3. Two reports have described a heels-over-head rotational chair designed to control

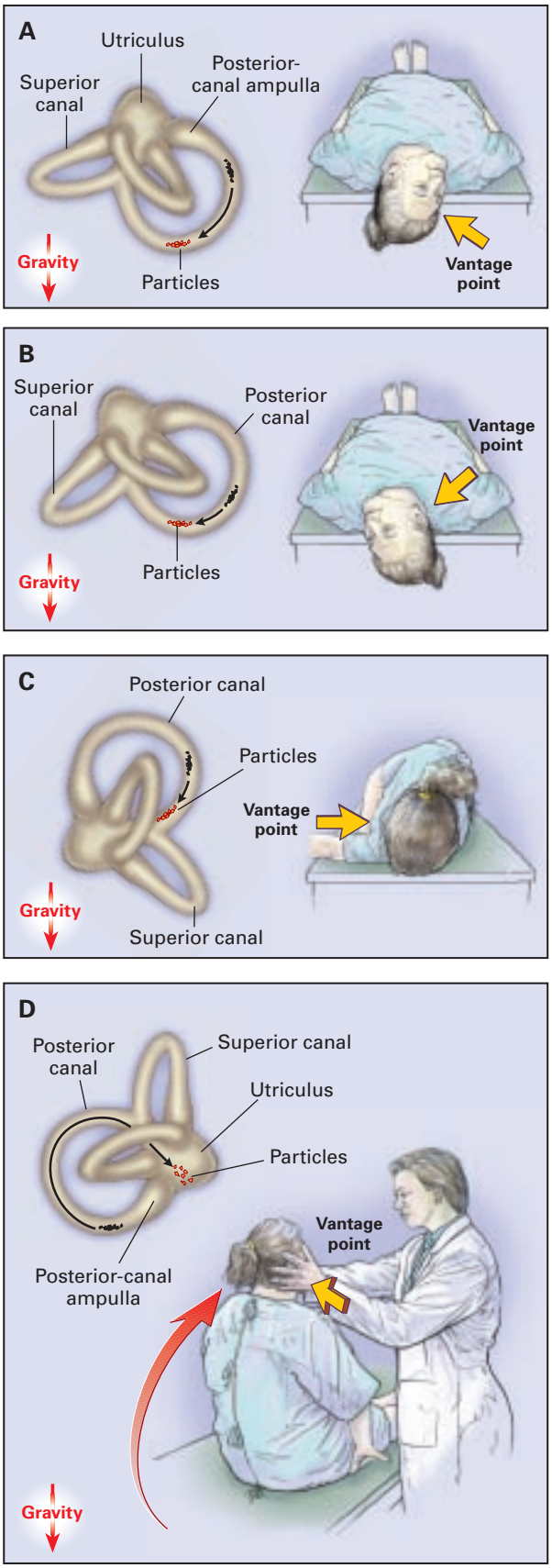

Figure 3. Bedside Maneuver for the Treatment of a Patient with Benign Paroxysmal Positional Vertigo Affecting the Right Ear.

The presumed position of the debris within the labyrinth during the maneuver is shown in each panel. The maneuver is a three-step procedure. First, a Dix–Hallpike test is performed with the patient's head rotated 45 degrees toward the right ear and the neck slightly extended with the chin pointed slightly upward. This position results in the patient's head hanging to the right (Panel A). Once the vertigo and nystagmus provoked by the Dix–Hallpike test cease, the patient's head is rotated about the rostral–caudal body axis until the left ear is down (Panel B). Then the head and body are further rotated until the head is face down (Panel C). The vertex of the head is kept tilted downward throughout the rotation. The maneuver usually provokes brief vertigo. The patient should be kept in the final, face-down position for about 10 to 15 seconds. With the head kept turned toward the left shoulder, the patient is brought into the seated position (Panel D). Once the patient is upright, the head is tilted so that the chin is pointed slightly downward.

for variations in technique[31,32] and to reduce neck movement.

Epley's initial publication on the use of bedside treatment for benign paroxysmal positional vertigo reported an 80 percent success rate after a single treatment session and a 100 percent success rate when there was more than one treatment session.[9] Subsequently, several open clinical trials reported success rates that ranged from 44 percent to 88 percent.[11,33-38] A randomized, controlled trial performed by Lynn et al.[39] reported a success rate of 89 percent after a single treatment session, as compared with a success rate of 23 percent in an untreated control group. In our own experience with 151 patients, the success rate was 87 percent after a single treatment session (unpublished data).

Often the vertigo recurs. Epley reported a recurrence rate of 30 percent over a 30-month follow-up period.[9] After a four-year follow-up period, we found a yearly 15 percent rate of recurrence after bedside treatment in 151 patients (unpublished data).

Other physical maneuvers have been used to treat patients with benign paroxysmal positional vertigo.[40,41] The maneuver described by Semont et al.[41] requires abrupt head movements; in our opinion, it is both more difficult to perform and more uncomfortable for the patient than the Epley maneuver. For patients whose history is highly suggestive of benign paroxysmal positional vertigo but who do not have the characteristic response to the Dix–Hallpike test, Brandt–Daroff exercises,[40] which involve repetitive side-to-side head movements, are often helpful. These exercises can also be useful for patients who have a relapse but choose not to return to a medical facility.

Although there is nearly uniform agreement regarding the head positions through which a patient should be moved to perform an Epley-type maneuver successfully, there are several small variations in technique. It is our practice during treatment to keep the patient's head in each position at least long enough for any provoked nystagmus or vertigo to resolve. During treatment, we use either a hand-held vibrator[9,42,43] or gentle manual vibration of the head. We prefer to repeat the maneuver until the patient is asymptomatic.[9] The patient should try to remain upright for 24 hours after treatment to reduce the likelihood of debris accumulating once again in the posterior semicircular canal. We do not routinely prescribe vestibular suppressants. These medications do not reduce the frequency of attacks of recurrent vertigo but may reduce the intensity of symptoms. They produce unwanted side effects, such as sleepiness, lethargy, and worsening of balance. Prolonged use of vestibular suppressants may delay the adaptation of the central nervous system to a peripheral vestibular abnormality, especially if treatment is continued for more than two weeks. Vestibular suppressants should be prescribed only after treatable causes of vertigo have been investigated. Usually, an as-needed dosage is preferable to a regular regimen of these medications.

For the rare patient with severe, intractable symptoms that are unresponsive to bedside treatment maneuvers, surgery is an option. There are two different procedures to disable the posterior semicircular canal. In singular neurectomy, the fibers of the eighth cranial nerve that form a synapse with the hair cells of the posterior semicircular canal are severed. In occlusion of the posterior semicircular canal, the goal is to interfere with the physiologic mechanism by which head movement is sensed by the posterior semicircular canal without damaging the other structures of the labyrinth or the cochlea. Both of these procedures have high success rates.[8,44-47]

Many patients present with symptoms and signs that suggest a more widespread balance disorder.[4,19] Some patients develop adaptive or maladaptive strategies to reduce positionally provoked vertigo. Such patients may benefit from a course of balance rehabilitation therapy,[48] in which patients perform specific combinations of head, eye, and body movements under the guidance of a skilled therapist to reduce symptoms and improve balance.

SUMMARY

Benign paroxysmal positional vertigo is a common disorder of the inner ear that should be suspected in all patients with a history of positionally provoked vertigo. The condition appears to be caused by free-floating debris in the posterior semicircular canal. The diagnosis is confirmed by eliciting characteristic symptoms and signs during the Dix–Hallpike test. Although benign paroxysmal positional vertigo is usually a self-limited disorder, treatment with a specific bedside maneuver is effective and can provide the patient immediate and long-lasting relief. Although many patients with positionally provoked vertigo have typical benign paroxysmal positional vertigo, physicians should be aware of nonbenign variants.

REFERENCES

1. Hotson JR, Baloh RW. Acute vestibular syndrome. N Engl J Med 1998; 339:680-5.

2. Drachman DA. A 69-year-old man with chronic dizziness. JAMA 1998; 280:2111-8. [Erratum, JAMA 1999;281:899.]

3. Dix MR, Hallpike CS. The pathology, symptomatology and diagnosis of certain common disorders of the vestibular system. Proc R Soc Med 1952;45:341-54.

4. Baloh RW, Honrubia V, Jacobson K. Benign positional vertigo: clinical and oculographic features in 240 cases. Neurology 1987;37:371-8.

5. Hall SF, Ruby RR, McClure JA. The mechanics of benign paroxysmal vertigo. J Otolaryngol 1979;8:151-8.

6. Epley JM. Positional vertigo related to semicircular canalithiasis. Otolaryngol Head Neck Surg 1995;112:154-61.

7. Parnes LS, McClure JA. Free-floating endolymph particles: a new operative finding during posterior semicircular canal occlusion. Laryngoscope 1992;102:988-92.

8. Welling DB, Parnes LS, O'Brien B, Bakaletz LO, Brackmann DE, Hinojosa R. Particulate matter in the posterior semicircular canal. Laryngoscope 1997;107:90-4.

9. Epley J. The canalith repositioning procedure: for treatment of benign paroxysmal positional vertigo. Otolaryngol Head Neck Surg 1992;107:399-404.

10. Brandt T, Steddin S, Eng D, Daroff R. Therapy for benign paroxysmal positioning vertigo, revisited. Neurology 1994;44:796-800.
11. Beynon GJ. A review of management of benign paroxysmal positional vertigo by exercise therapy and by repositioning manoeuvres. Br J Audiol 1997;31:11-26.
12. Sakata E, Ohtsu K, Itoh Y. Positional nystagmus of benign paroxysmal type (BPPN) due to cerebellar vermis lesions: pseudo-BPPN. Acta Otolaryngol Suppl (Stockh) 1991;481:254-7.
13. Schuknecht HF. Cupulolithiasis. Arch Otolaryngol 1969;90:765-78.
14. Gacek RR. Cupulolithiasis and posterior ampullary nerve transection. Ann Otol Rhinol Laryngol 1984;93:Suppl 112:25-30.
15. Schuknecht HF, Ruby RRF. Cupulolithiasis. Adv Otorhinolaryngol 1973;20:434-43.
16. Moriarty B, Rutka J, Hawke M. The incidence and distribution of cupular deposits in the labyrinth. Laryngoscope 1992;102:56-9.
17. Naganuma H, Kohut RI, Ryu JH, et al. Basophilic deposits on the cupula: preliminary findings describing the problems involved in studies regarding the incidence of basophilic deposits on the cupula. Acta Otolaryngol Suppl (Stockh) 1996;524:9-15.
18. Lanska D, Remler B. Benign paroxysmal positioning vertigo: classic descriptions, origins of the provocative positioning technique, and conceptual developments. Neurology 1997;48:1167-77.
19. McClure J, Lycett P, Rounthwaite J. Vestibular dysfunction associated with benign paroxysmal vertigo. Laryngoscope 1977;87:1434-42.
20. Seidman SH, Leigh RH. The human torsional vestibulo-ocular reflex during rotation about an earth-vertical axis. Brain Res 1989;504:264-8.
21. Gregorius FK, Crandall PH, Baloh RW. Positional vertigo with cerebellar astrocytoma. Surg Neurol 1976;6:283-6.
22. Dunniway HM, Welling DB. Intracranial tumors mimicking benign paroxysmal positional vertigo. Otolaryngol Head Neck Surg 1998;118:429-36.
23. Froehling DA, Silverstein MD, Mohr DN, Beatty CW, Offord KP, Ballard DJ. Benign positional vertigo: incidence and prognosis in a population-based study in Olmsted County, Minnesota. Mayo Clin Proc 1991;66:596-601.
24. Mizukoshi K, Watanabe Y, Shojaku H, Okubo J, Watanabe I. Epidemiological studies on benign paroxysmal positional vertigo in Japan. Acta Otolaryngol Suppl (Stockh) 1988;447:67-72.
25. Nedzelski JM, Barber HO, McIlmoyl L. Diagnoses in a dizziness unit. J Otolaryngol 1986;15:101-4.
26. Fife T. Recognition and management of horizontal canal benign positional vertigo. Am J Otol 1998;19:345-51.
27. McClure JA. Horizontal canal BPV. J Otolaryngol 1985;14:30-5.
28. Lempert T, Tiel-Wilck K. A positional maneuver for treatment of horizontal-canal benign positional vertigo. Laryngoscope 1996;106:476-8.
29. Nuti D, Agus G, Barbieri MT, Passali D. The management of horizontal-canal paroxysmal positional vertigo. Acta Otolaryngol (Stockh) 1998; 118:455-60.
30. Watson CP, Terbrugge K. Positional nystagmus of the benign paroxysmal type with posterior fossa medulloblastoma. Arch Neurol 1982;39: 601-2.
31. Lempert T, Wolsley C, Davies R, Gresty MA, Bronstein AM. Three hundred sixty-degree rotation of the posterior semicircular canal for treatment of benign positional vertigo: a placebo-controlled trial. Neurology 1997;49:729-33.
32. Furman JM, Cass SP, Briggs BC. Treatment of benign positional vertigo using heels-over-head rotation. Ann Otol Rhinol Laryngol 1998;107: 1046-53.
33. Herdman SJ, Tusa RJ, Zee DS, Proctor LR, Mattox DE. Single treatment approaches to benign paroxysmal positional vertigo. Arch Otolaryngol Head Neck Surg 1993;119:450-4.
34. Parnes LS, Price-Jones RG. Particle repositioning maneuver for benign paroxysmal positional vertigo. Ann Otol Rhinol Laryngol 1993;102:325-31.
35. Blakely BW. A randomized, controlled assessment of the canalith repositioning maneuver. Otolaryngol Head Neck Surg 1994;110:391-6.
36. Pool AF, Rose DE, Green JD. Clinical results of the modified canalith repositioning maneuver. Am J Audiol 1994;3:55-7.
37. Weider DJ, Ryder CJ, Stram JR. Benign paroxysmal positional vertigo: analysis of 44 cases treated by the canalith repositioning procedure of Epley. Am J Otol 1994;15:321-6.
38. Welling DB, Barnes DE. Particle repositioning maneuver for benign paroxysmal positional vertigo. Laryngoscope 1994;104:946-9.
39. Lynn S, Pool A, Rose D, Brey R, Suman V. Randomized trial of the canalith repositioning procedure. Otolaryngol Head Neck Surg 1995;113: 712-20.
40. Brandt T, Daroff RB. Physical therapy for benign paroxysmal positional vertigo. Arch Otolaryngol 1980;106:484-5.
41. Semont A, Freyss G, Vitte E. Curing the BPPV with a liberatory maneuver. Adv Otorhinolaryngol 1988;42:290-3.
42. Li JC. Mastoid oscillation: a critical factor for success in canalith repositioning procedure. Otolaryngol Head Neck Surg 1995;112:670-5.
43. Levy-Reis I, Uddin MK, Hain TC. Vibration does not improve results of the Epley maneuver. Neurology 1997;48:Suppl:A134-A135.
44. Parnes LS, McClure JA. Posterior semicircular canal occlusion for intractable benign paroxysmal positional vertigo. Ann Otol Rhinol Laryngol 1990;99:330-4.
45. Hawthorne M, el-Naggar M. Fenestration and occlusion of posterior semicircular canal for patients with intractable benign paroxysmal positional vertigo. J Laryngol Otol 1994;108:935-9.
46. Gacek RR. Technique and results of singular neurectomy for the management of benign paroxysmal positional vertigo. Acta Otolaryngol (Stockh) 1995;115:154-7.
47. Zappia JJ. Posterior semicircular canal occlusion for benign paroxysmal positional vertigo. Am J Otol 1996;17:749-54.
48. Herdman SJ. Advances in the treatment of vestibular disorders. Phys Ther 1997;77:602-18.